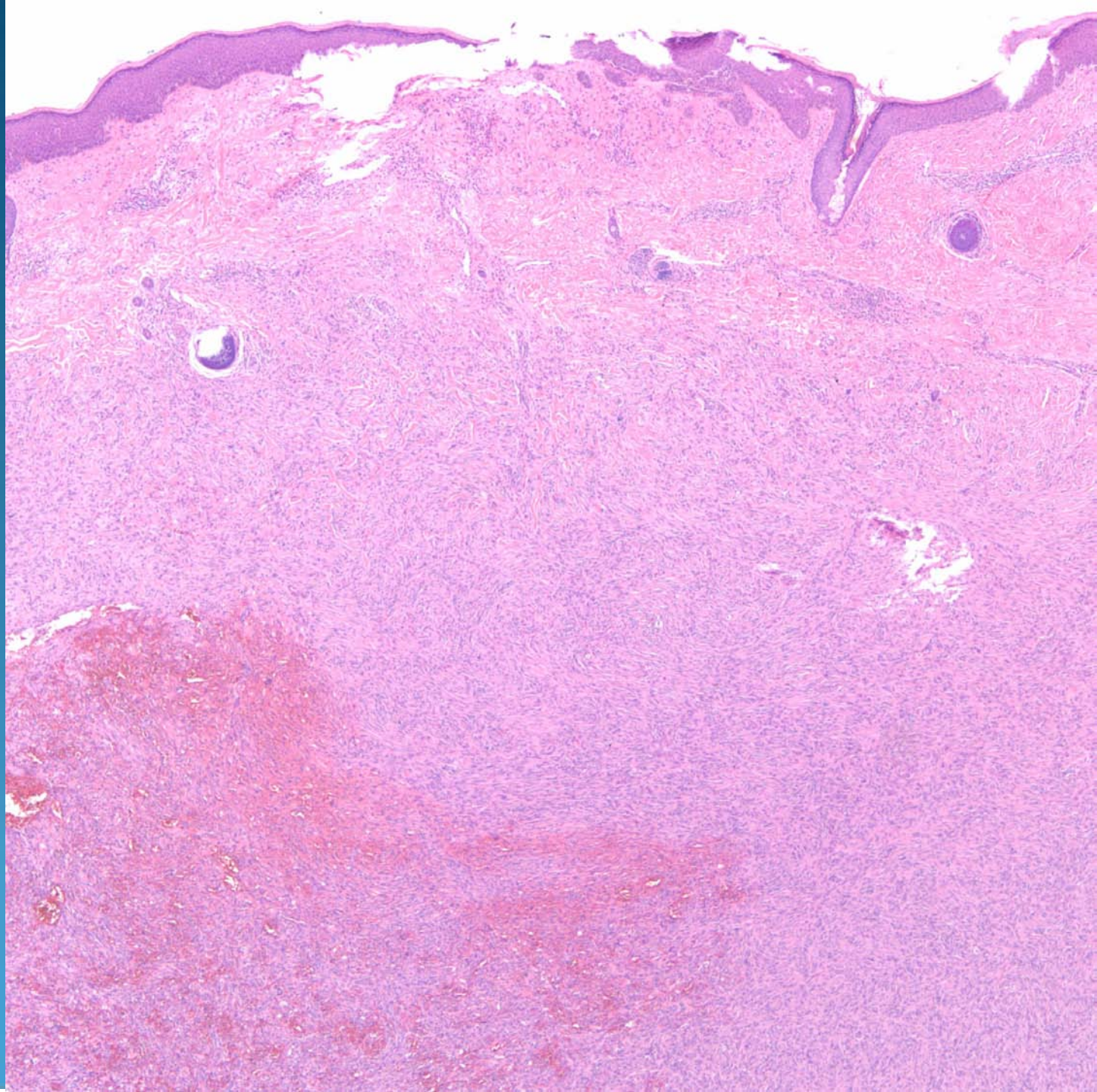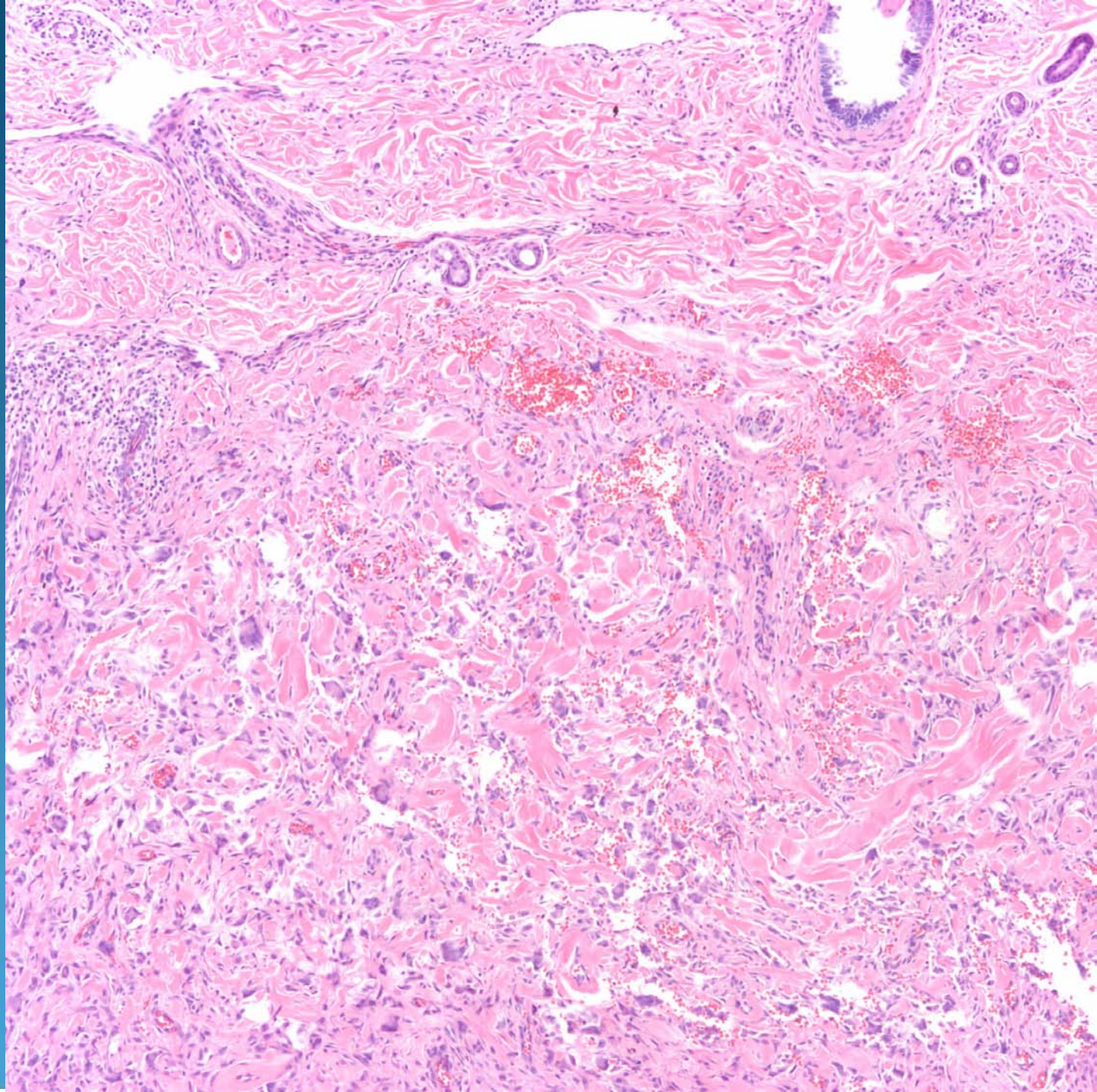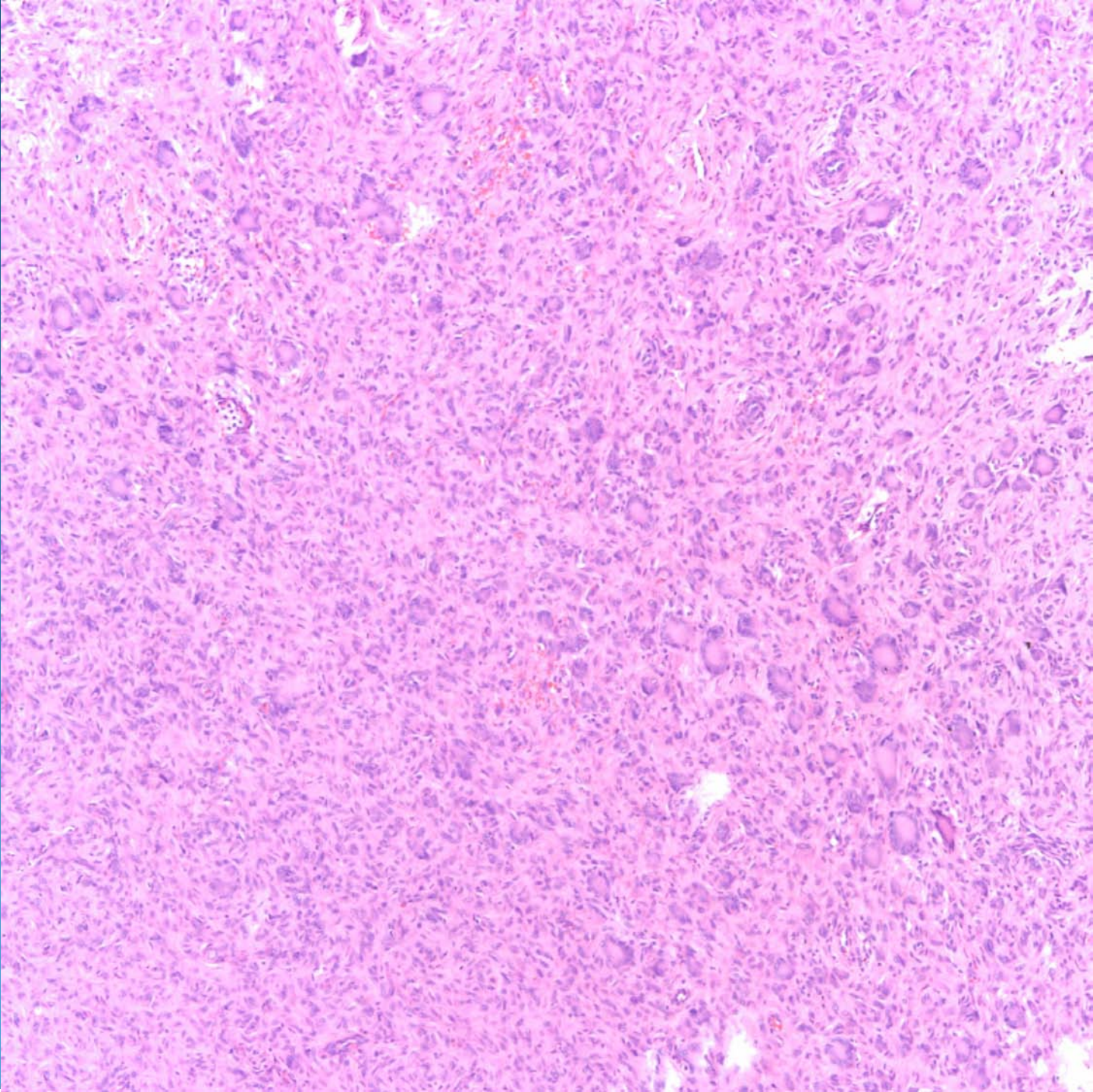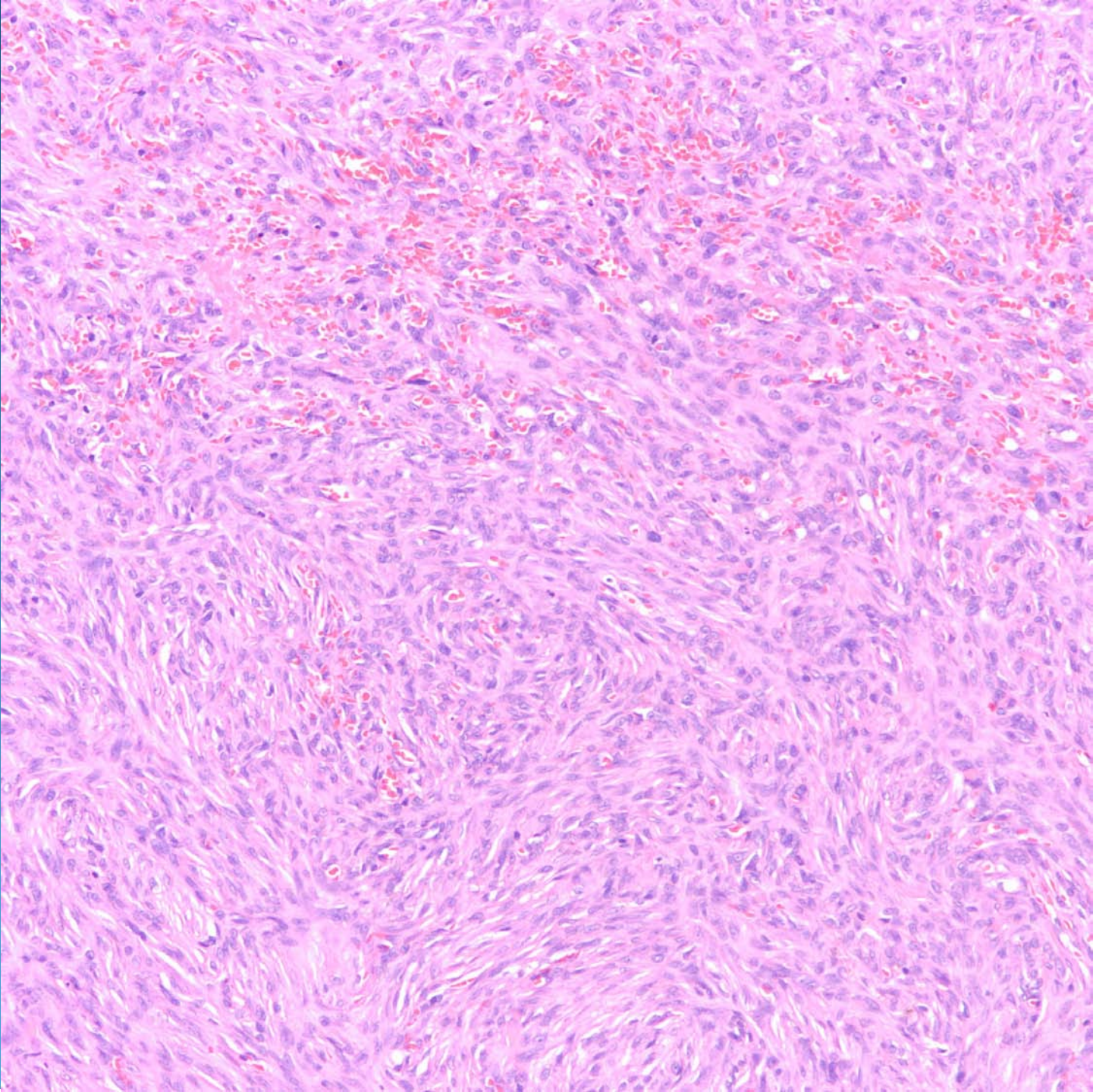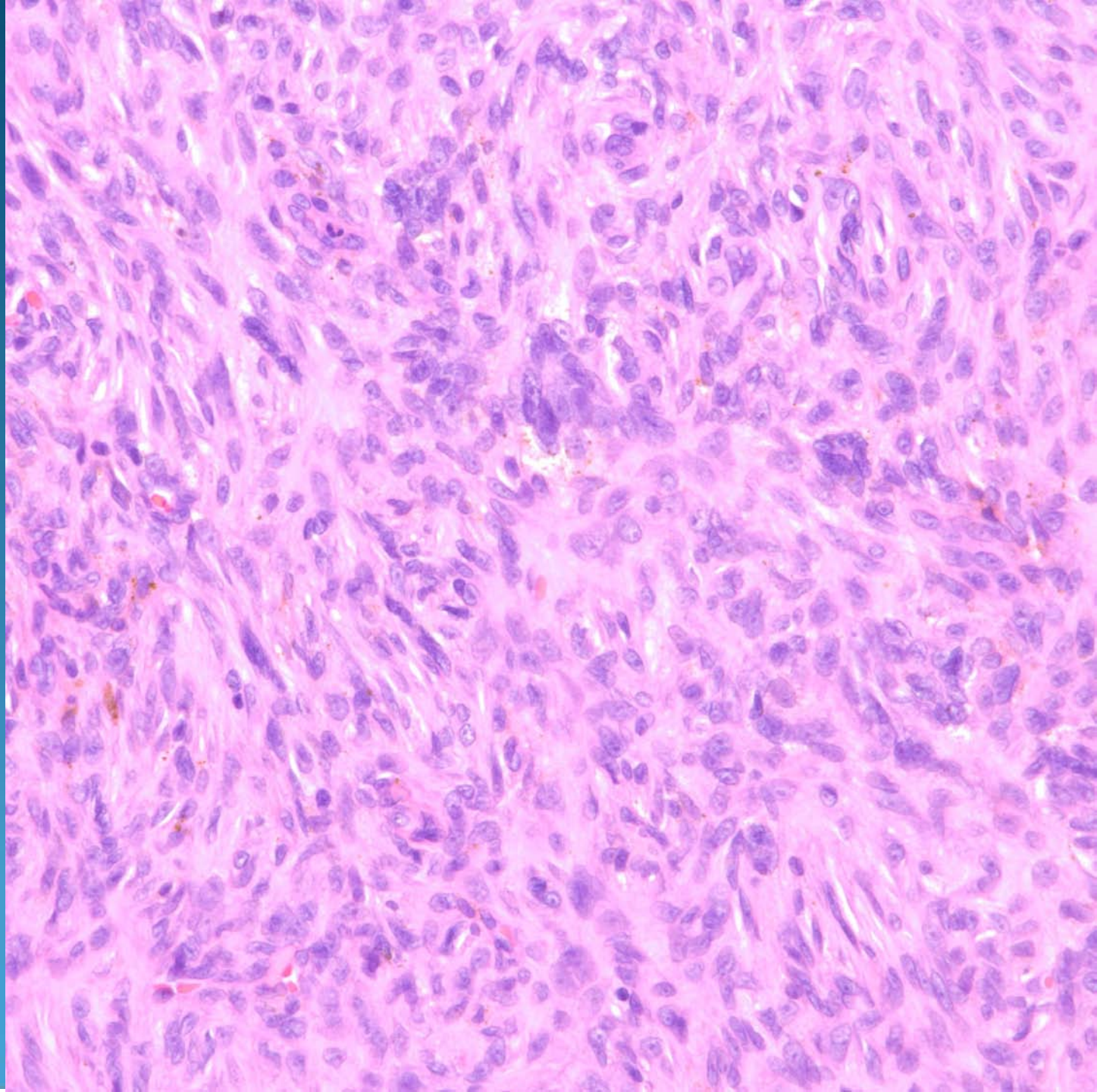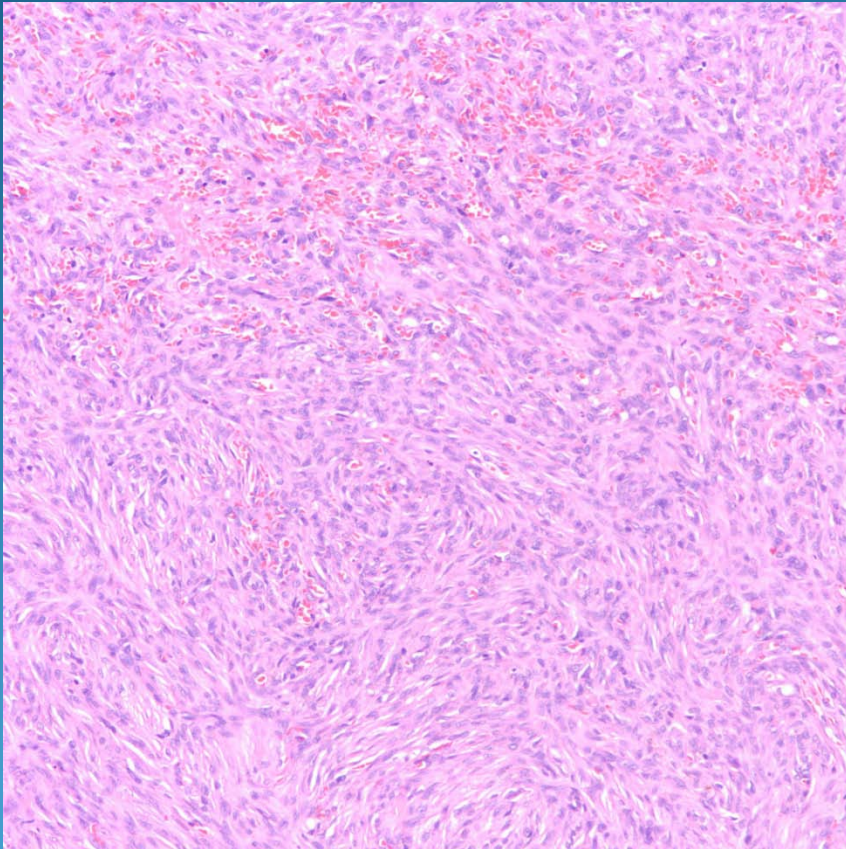


Dermatofibroma, Cellular

Pearls



- Resembles conventional DF but increased cellularity
- Look for familiar collagen entrapment and Touton type giant cells
- Cellular areas may approach storiform configuration and have increased MFs-but no atypical MFs